



LIDO

MASTERCLASS

Instruction Hand-Assisted
Retroperitoneoscopic
Donor Nephrectomy

29 June– 1 July, 2022

Robert Minnee

Conflict of interest

I declare I have no conflict of interest

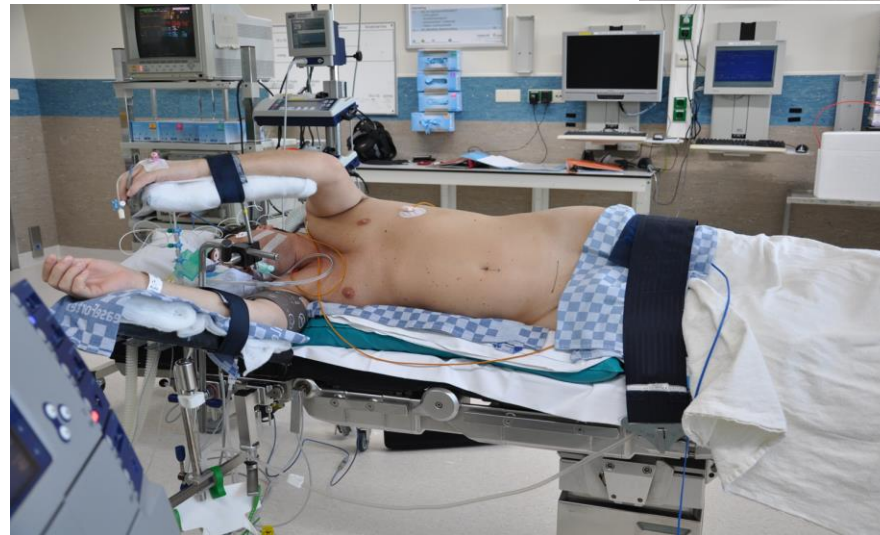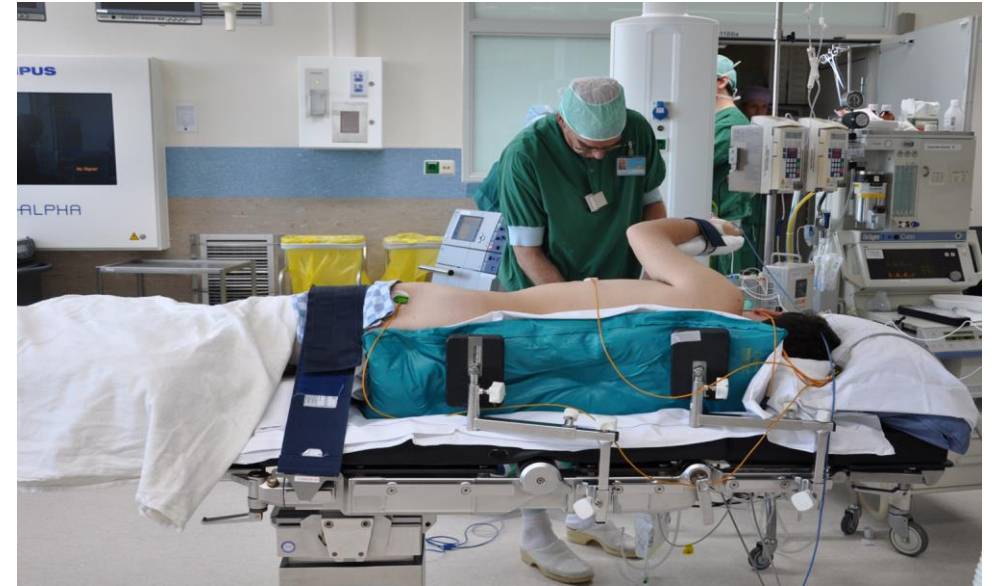Please do not share this presentation on social media



Thank you

Positioning the patient

- Flank position with operative side up
- Vacuum mattress
- Dorsal supports
- Edge of the table




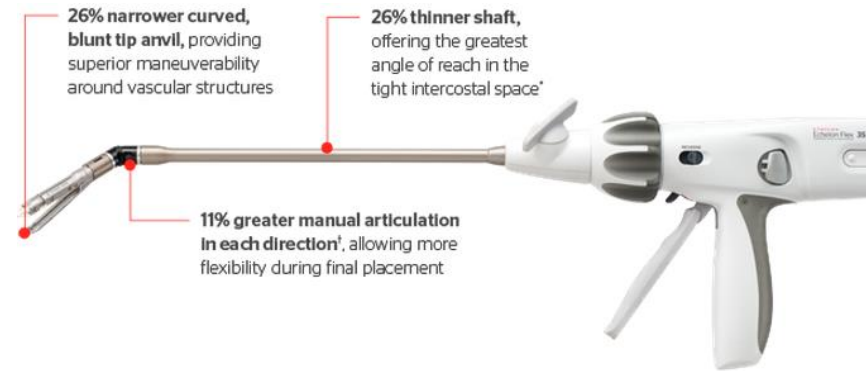
Points of interest

- **Mind the traction on the brachial plexus**
- **Explicit dorsal support of lumbar region with vacuum mattress**
- **Anti-embolism stockings**
- **CAD insertion after anesthesia**

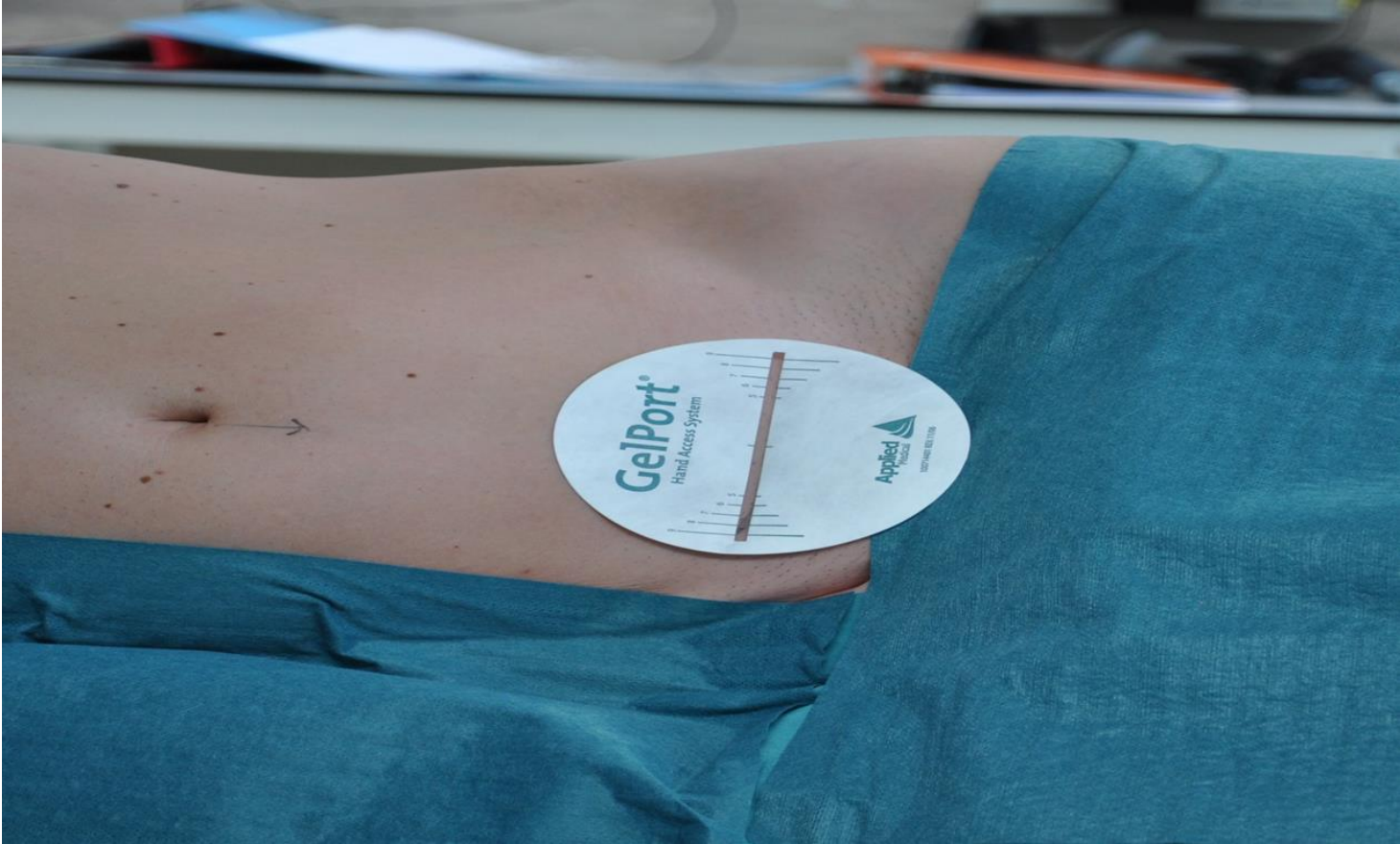

Laparoscopic instruments

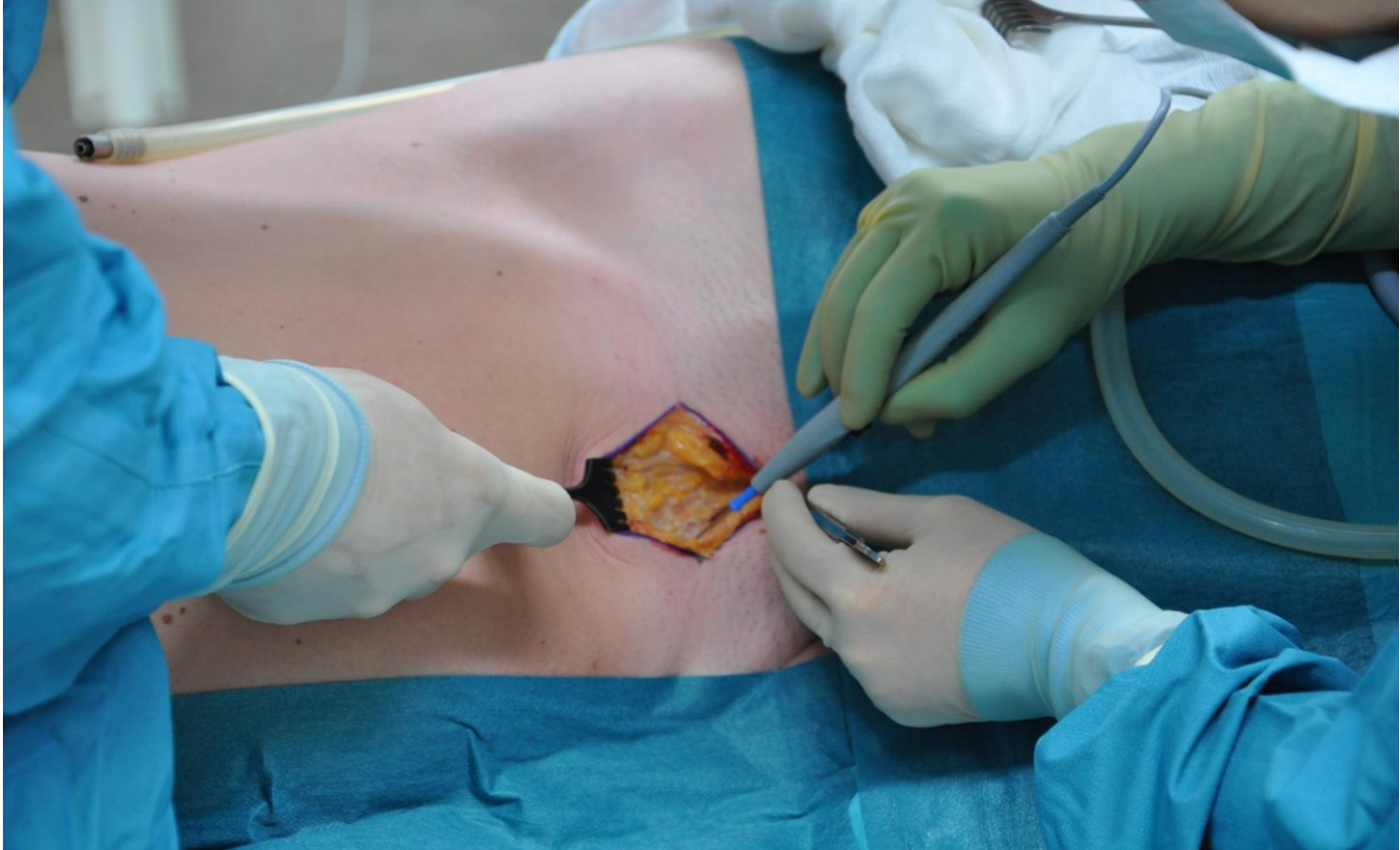- 30° angle camera
- Ultrasonic shears (Harmonic Ace, Thunderbeat, Sonicision)
- Atraumatic forceps
- Gelport
- Laparoscopic scissors
- Laparoscopic vascular stapling device
- Laparoscopic clips
- Vessel loops



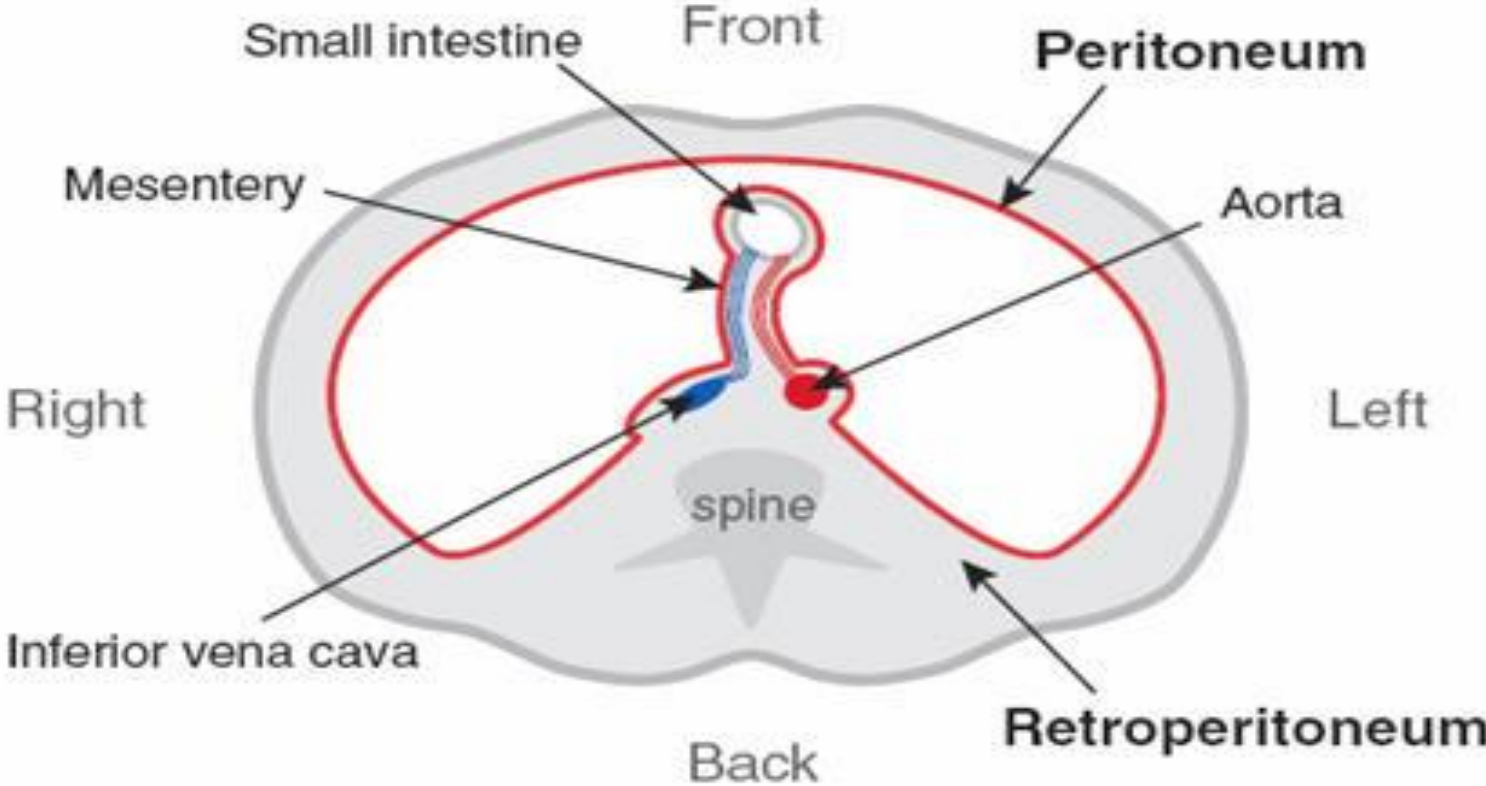
Pfannenstiel incision



Pfannenstiel incision

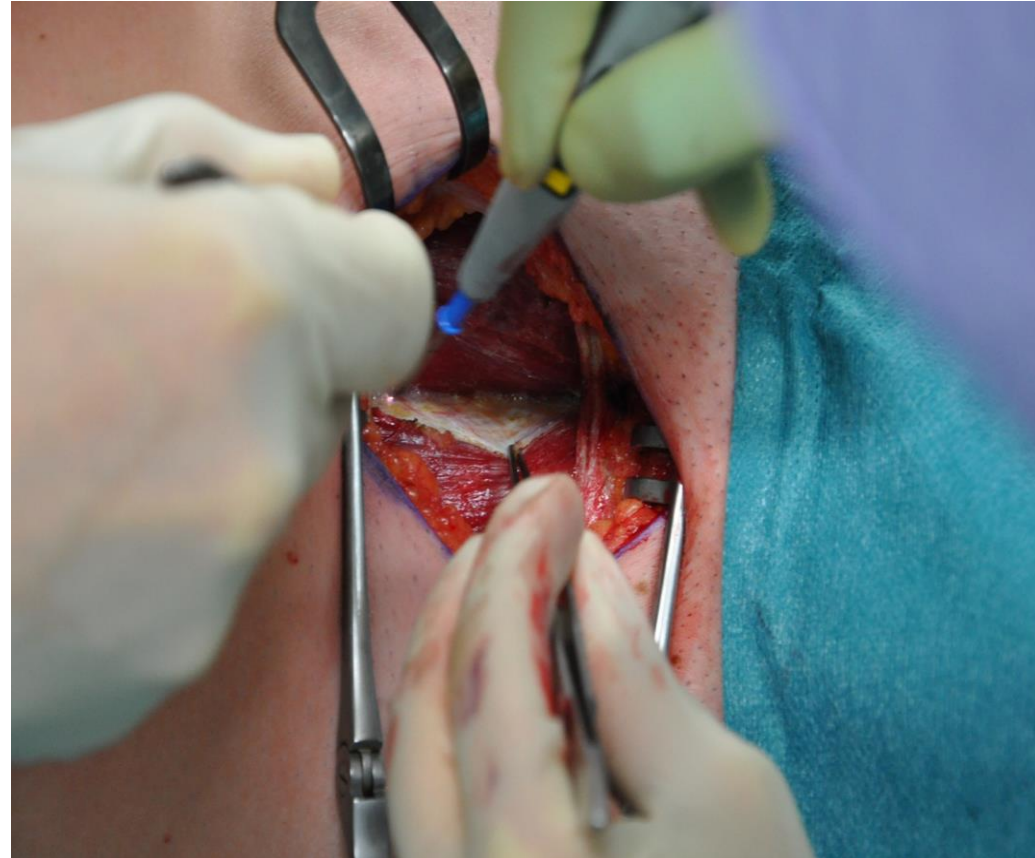


Retroperitoneum



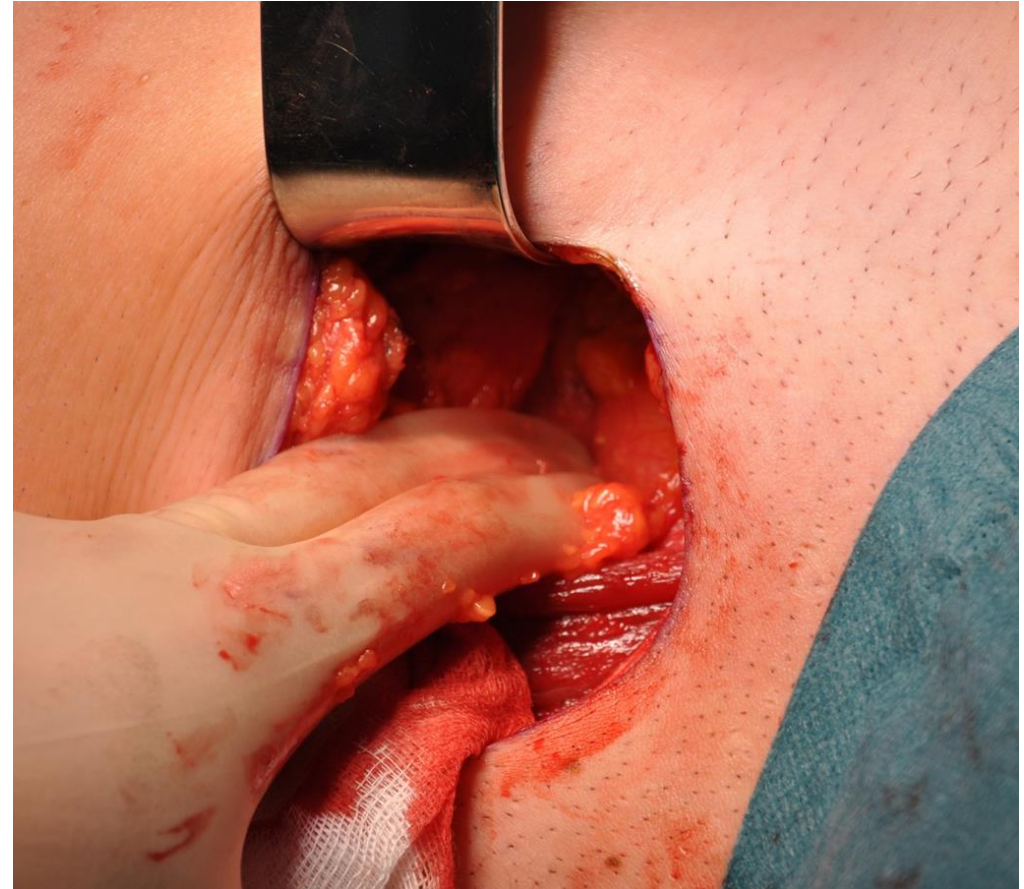
Pfannenstiel incision

- Open linea alba
- Preserve peritoneum



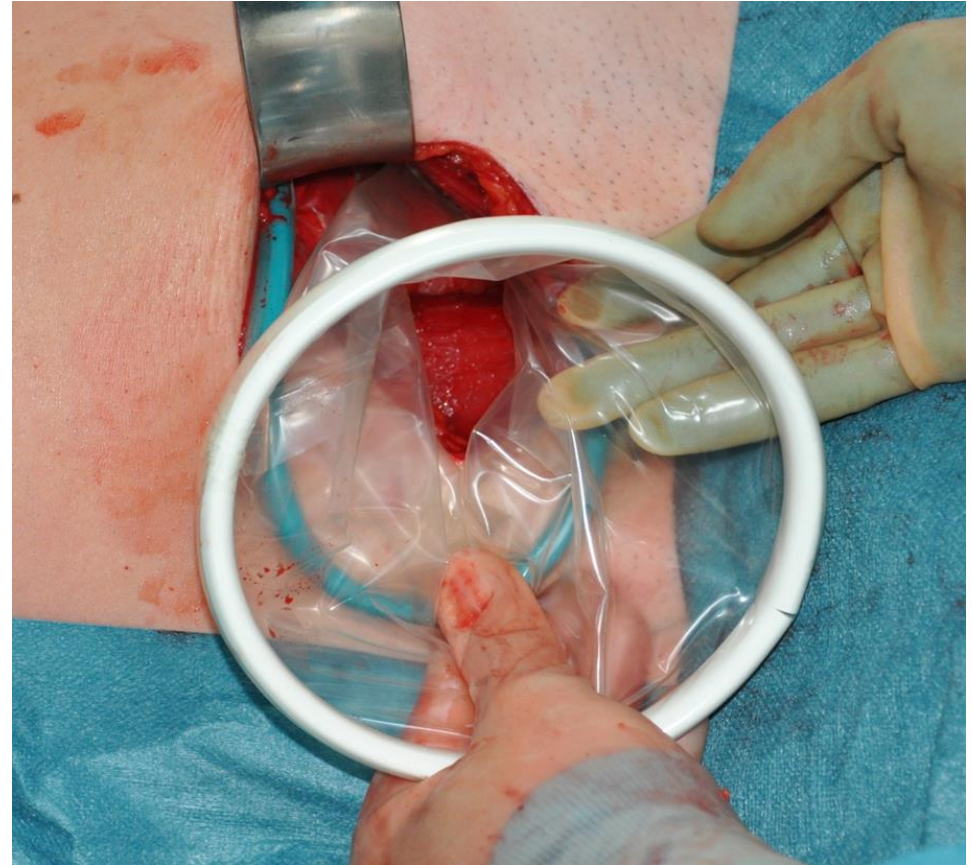
Pfannenstiel incision

- Develop peritoneum behind the rectus muscle
- Beware of epigastric vessels
- Devide round ligament if needed

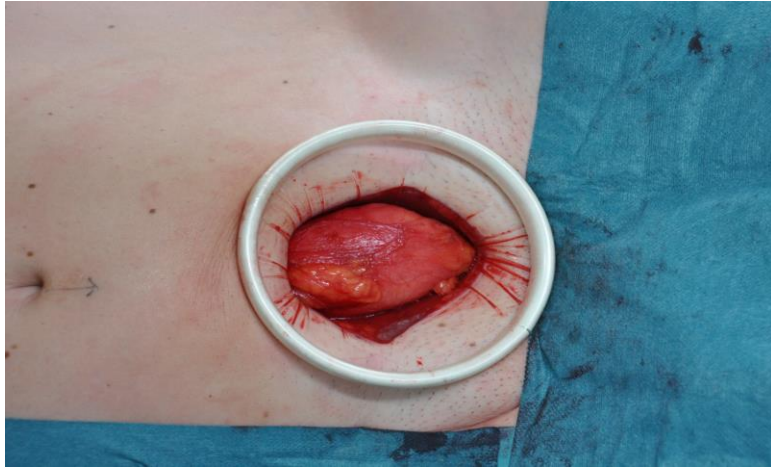


Gelport placement

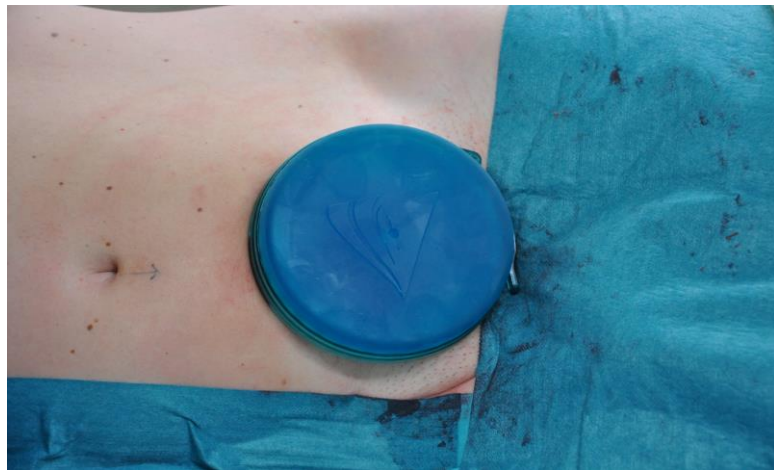- **Internal ring is locked behind rectus muscle**
- **Outer ring is twisted inward to secure position**



Gelport placement

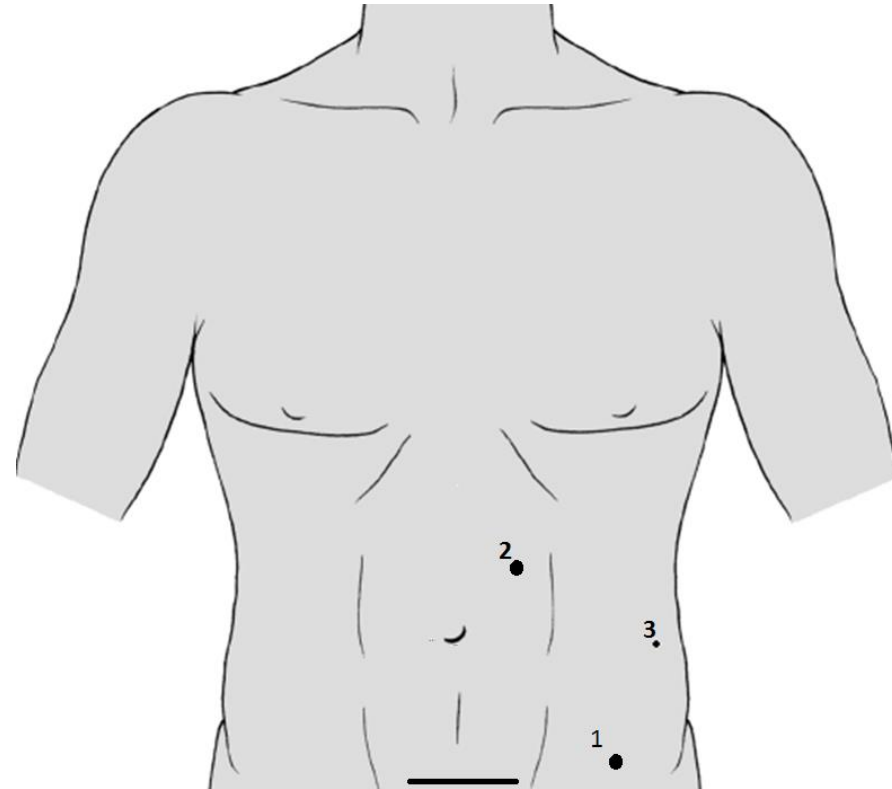


- **Secure gelport on outer ring with clasp**

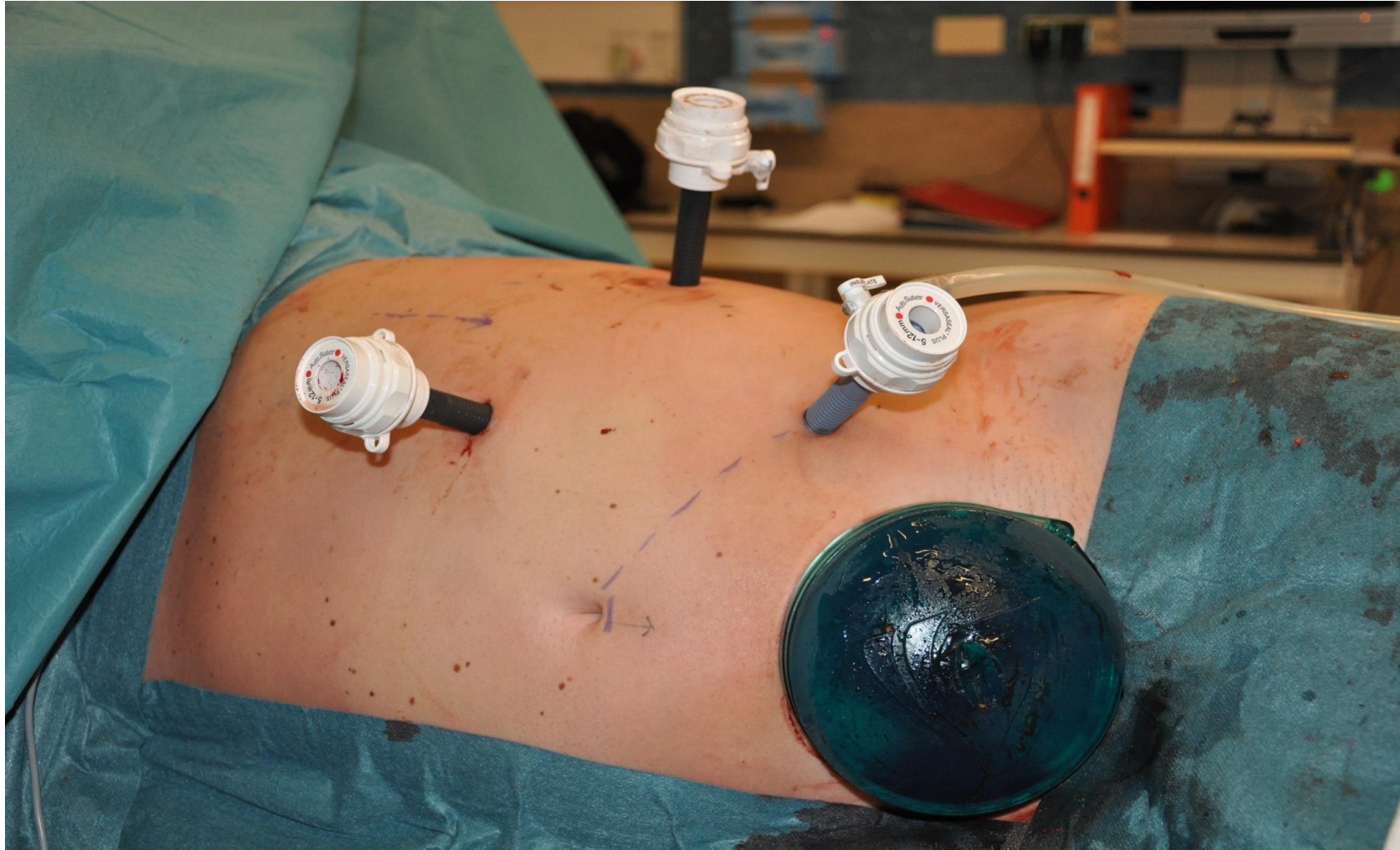


Trocar placement left-sided HARP nephrectomy

- 10 mm trocar pararectal lateral to the pfannenstiel(1)
- paraumbilical bladeless 10-12 mm tip trocar after mobilisation of the peritoneum (2)
- 5 mm trocar laterally above iliac spine (3)

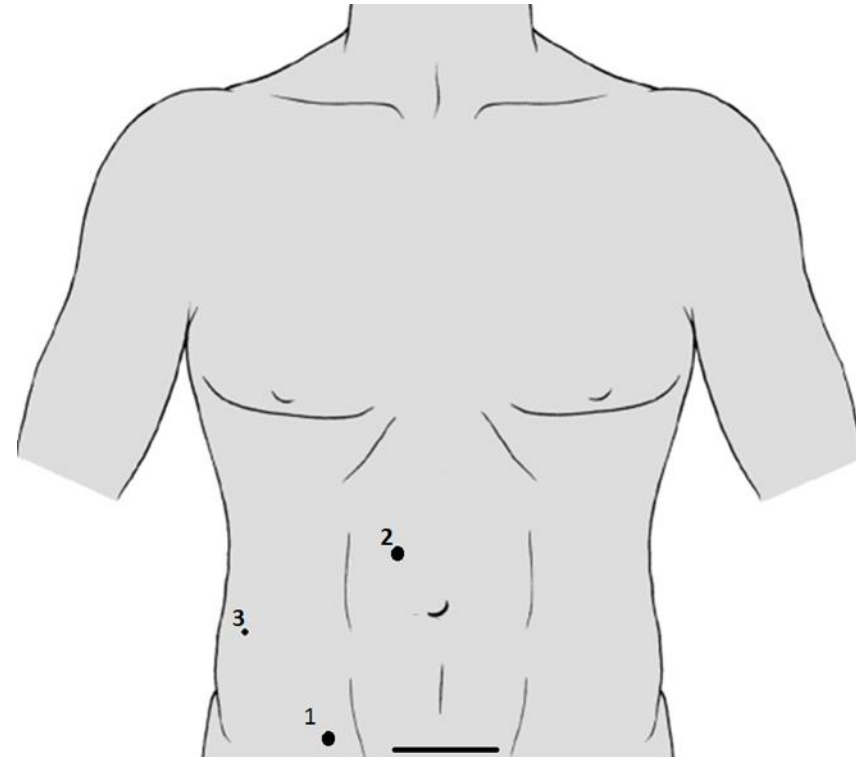


Trocar position



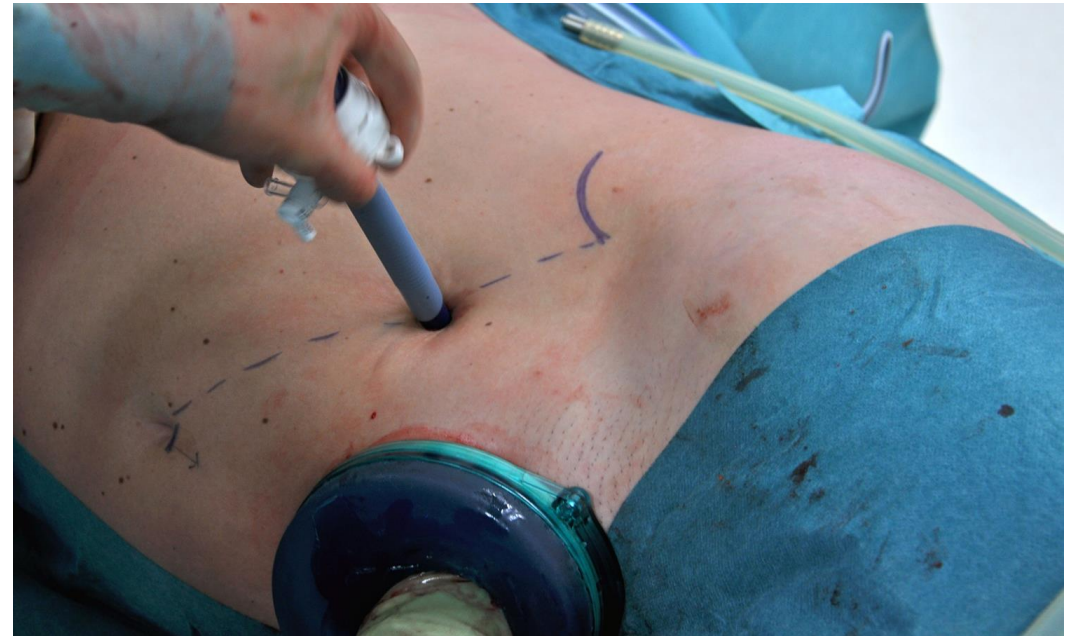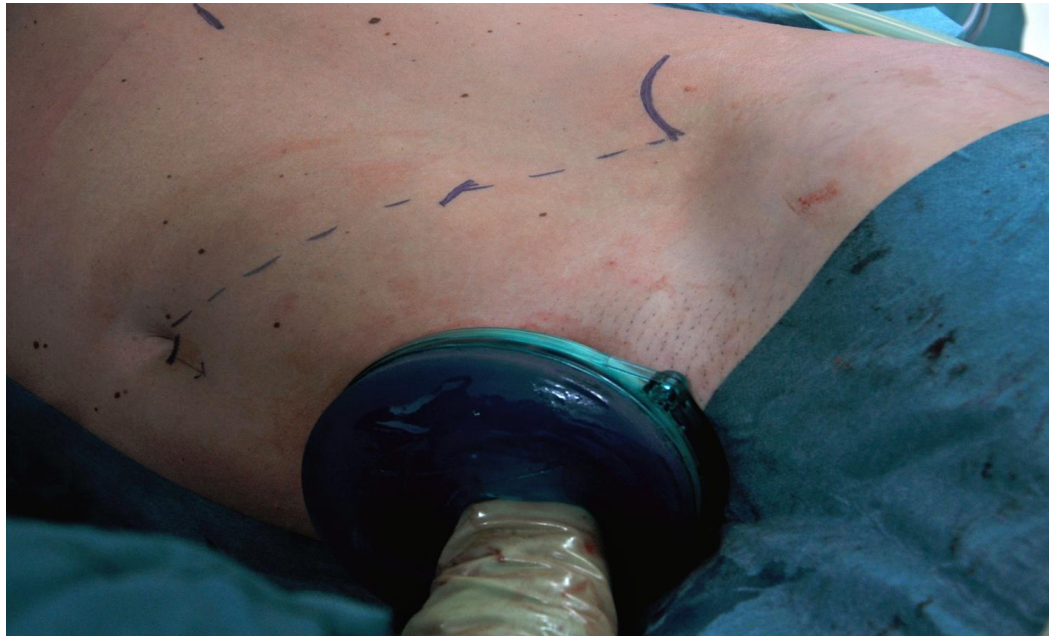
Trocar placement right-sided HARP nephrectomy

- 10 mm trocar pararectal end lateral to the pfannenstiel (1)
- paraumbilical bladeless 10-12 mm tip trocar after mobilisation of the peritoneum (2)
- 5 mm trocar laterally above iliac spine (3)



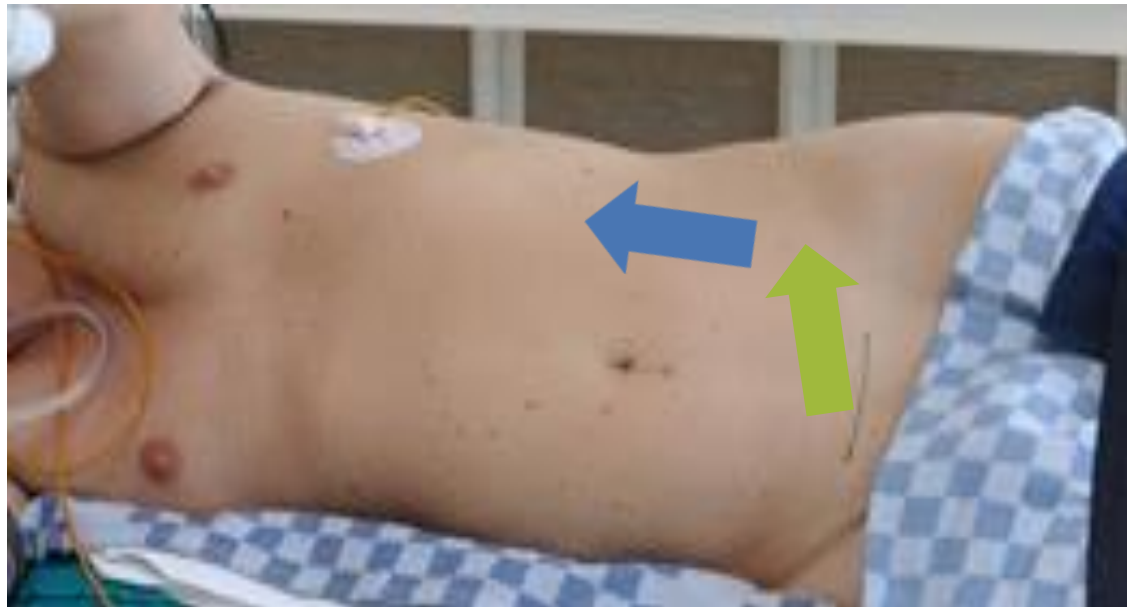
Trocar placement

- Insert bladeless trocar towards the palm of your hand, protecting peritoneum

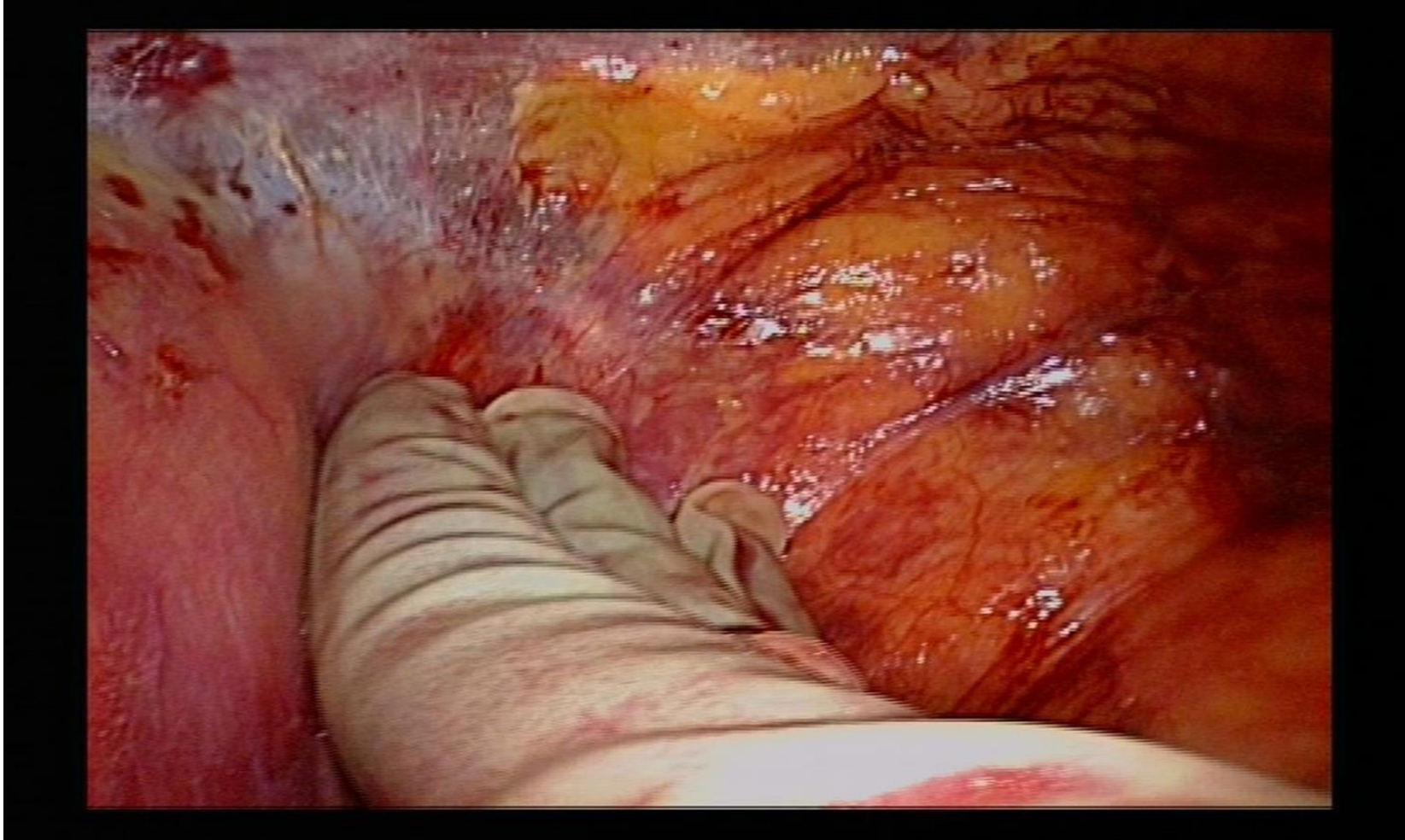


Development retroperitoneal plane

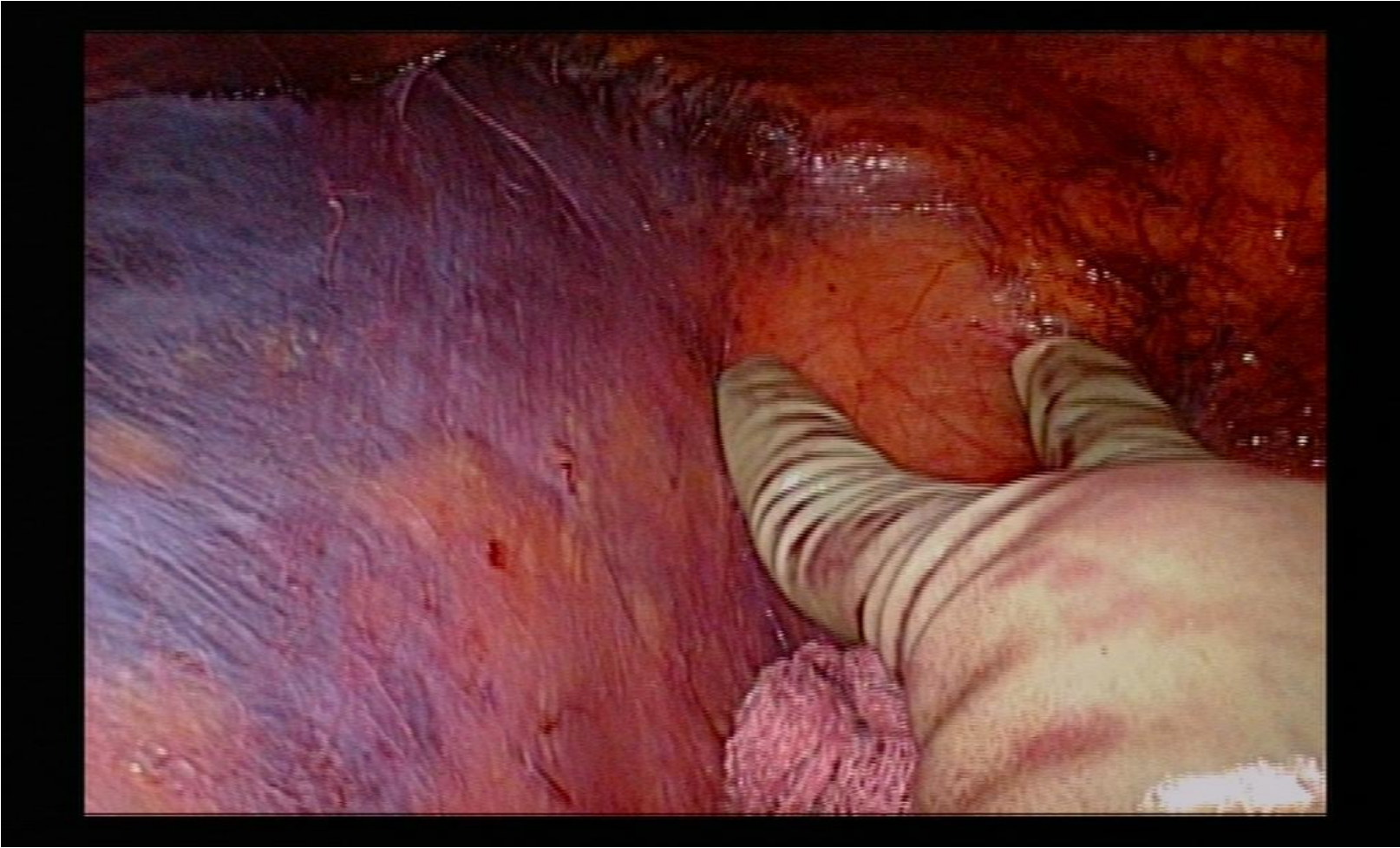
- Progress toward the iliac spine
- Feel the iliac artery dorsal to your trajectory
- Move in a cranial direction from the iliac spine towards the lower rib



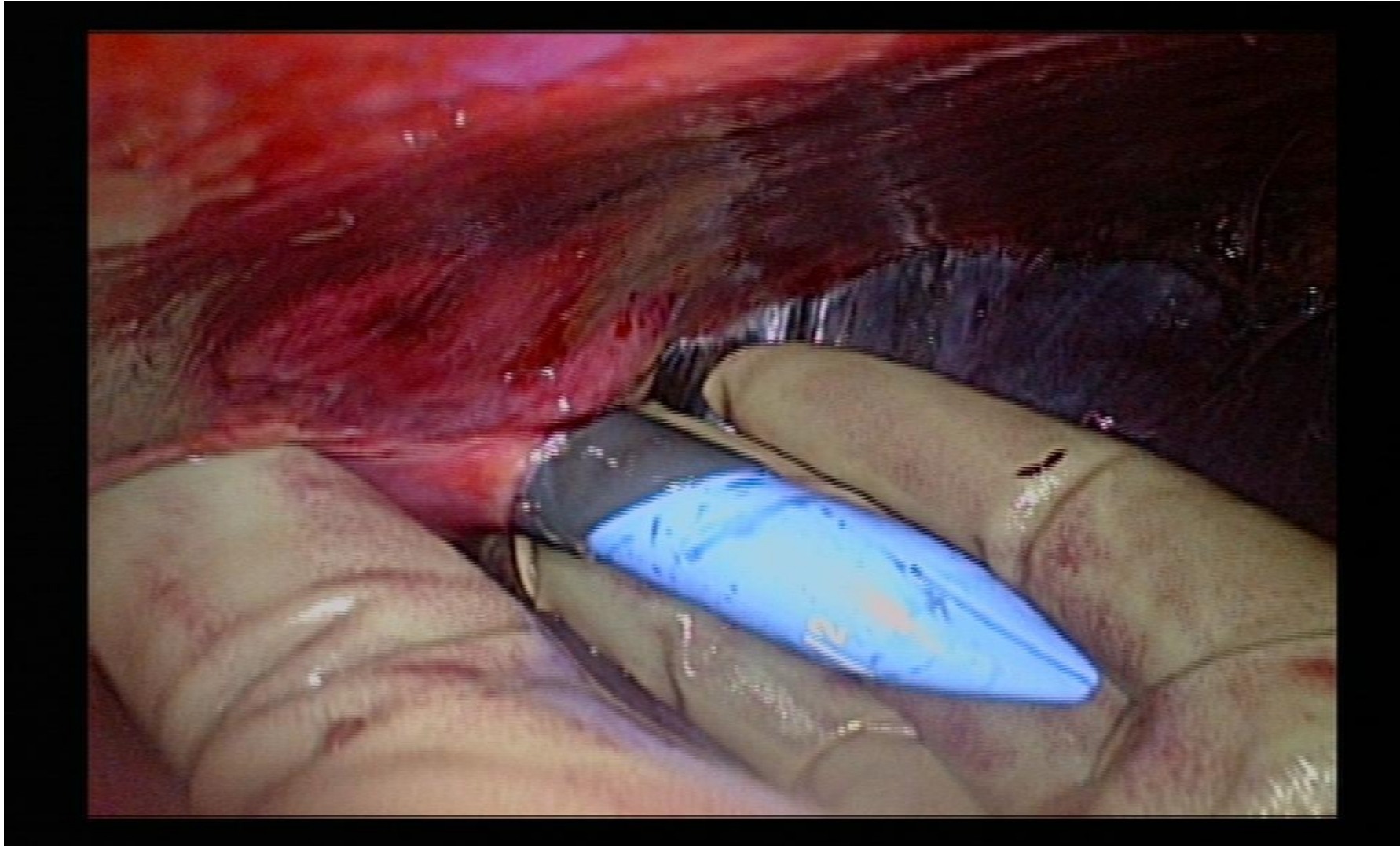
Development retroperitoneal plane



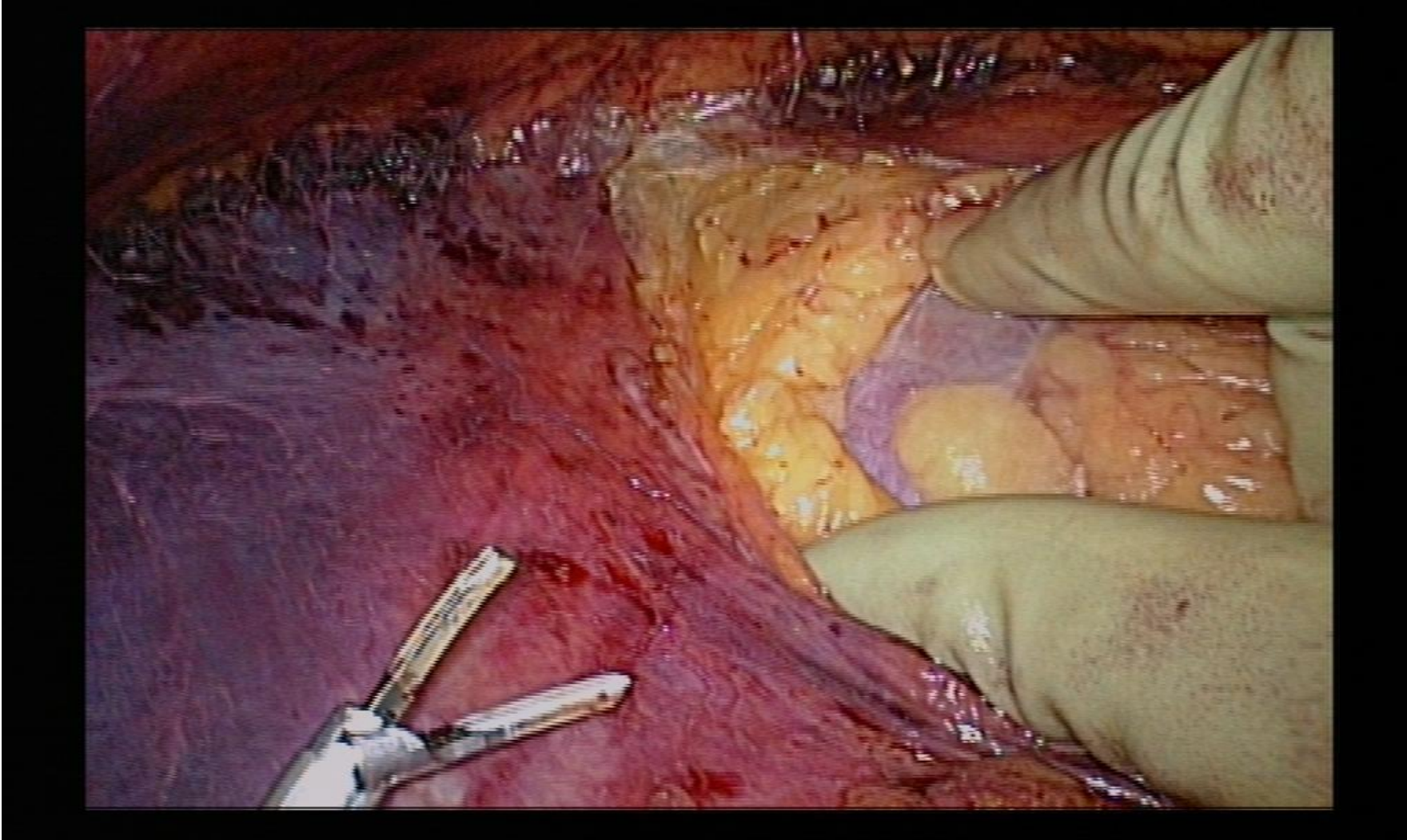
Identification kidney



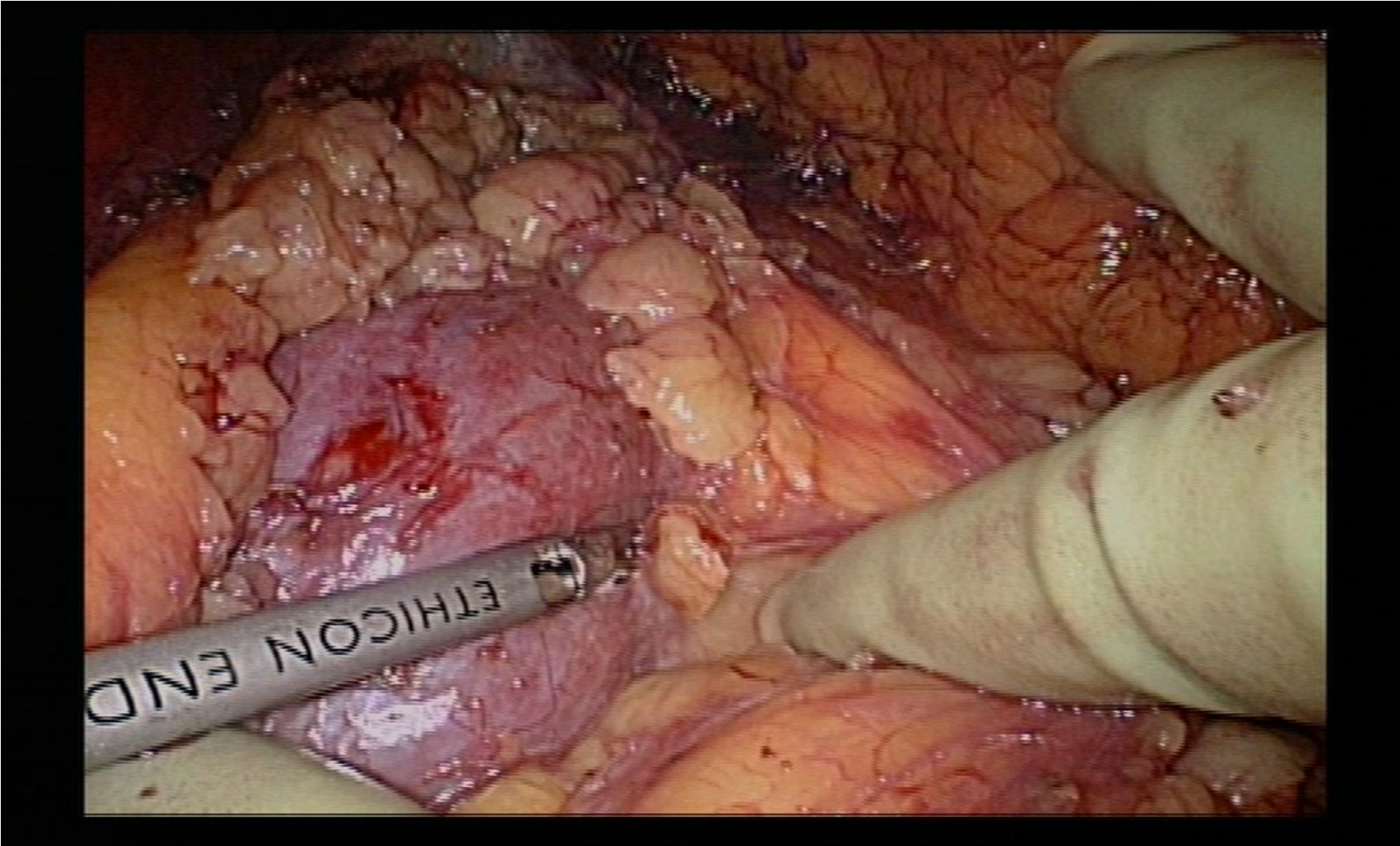
Trocar placement: surgeon



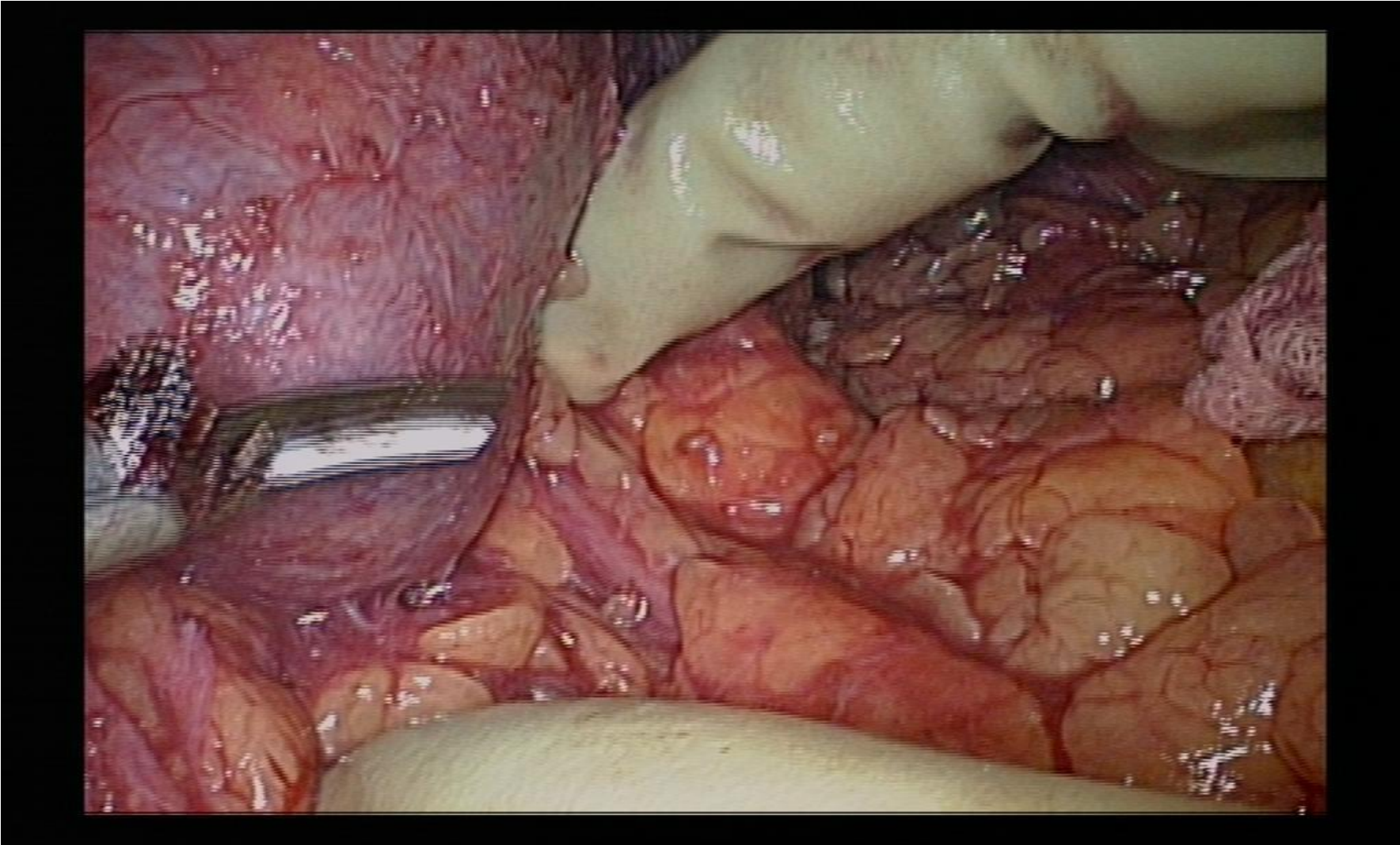
Dissection of Gerota



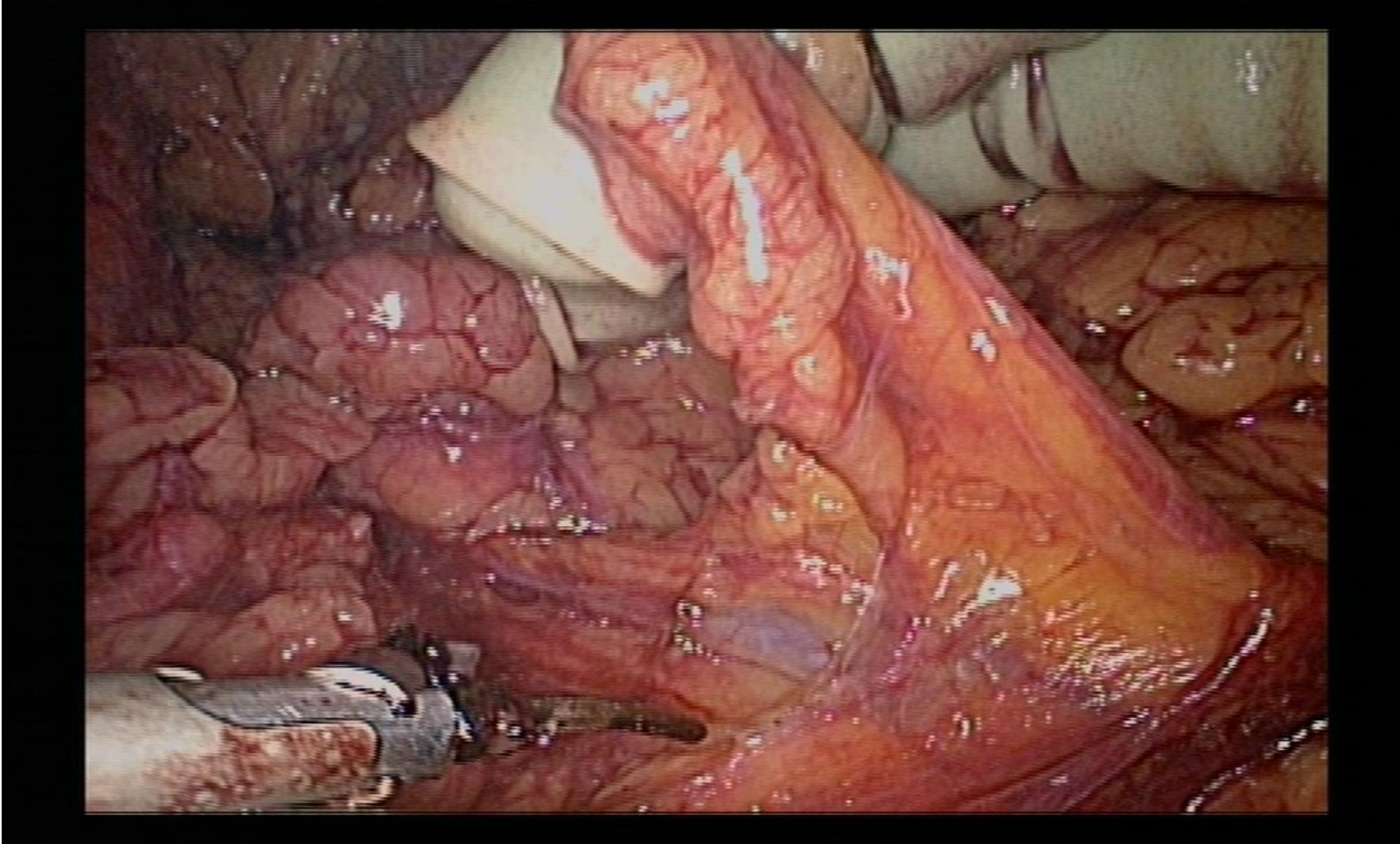
Mobilisation of the kidney



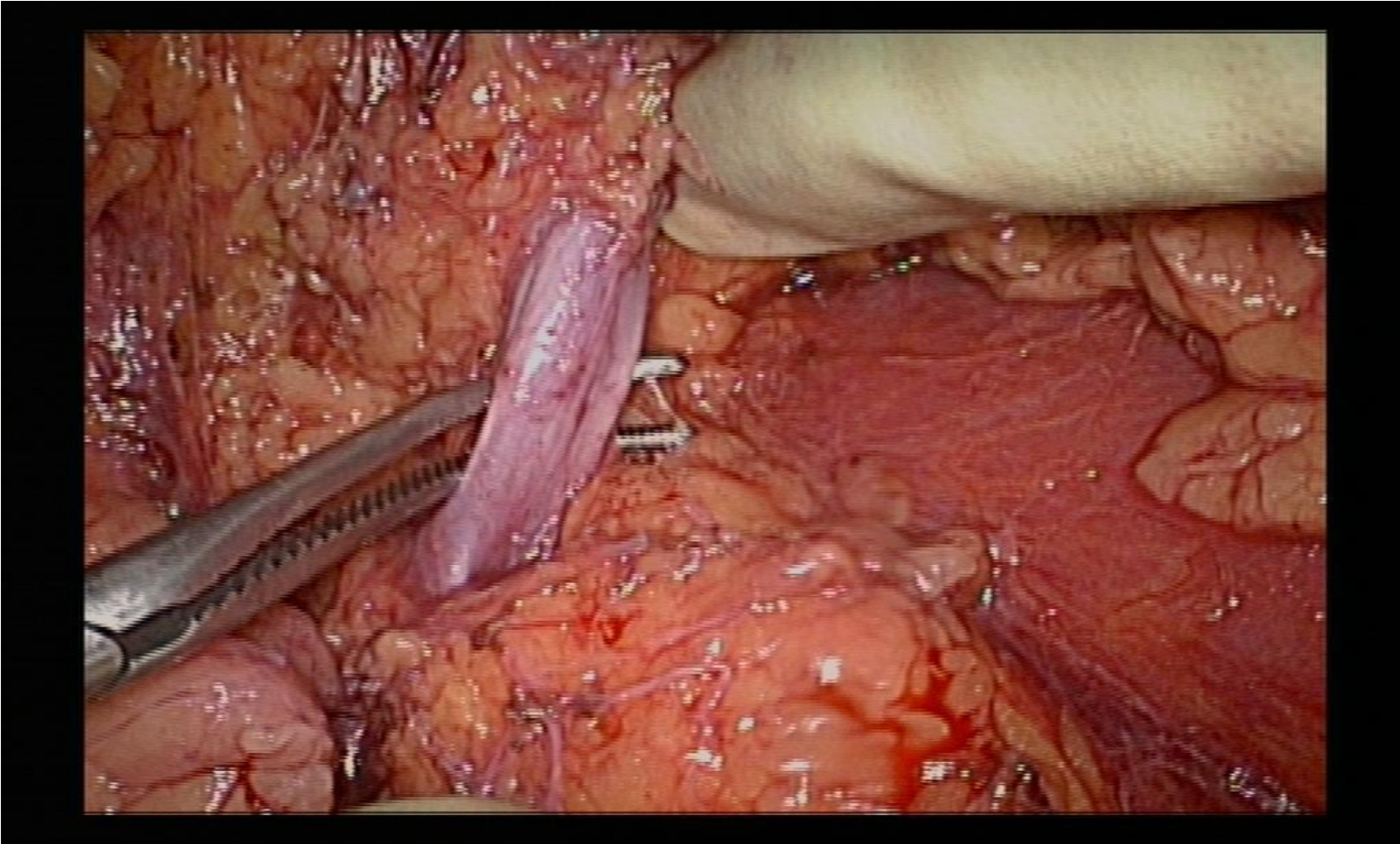
Dissection ureter



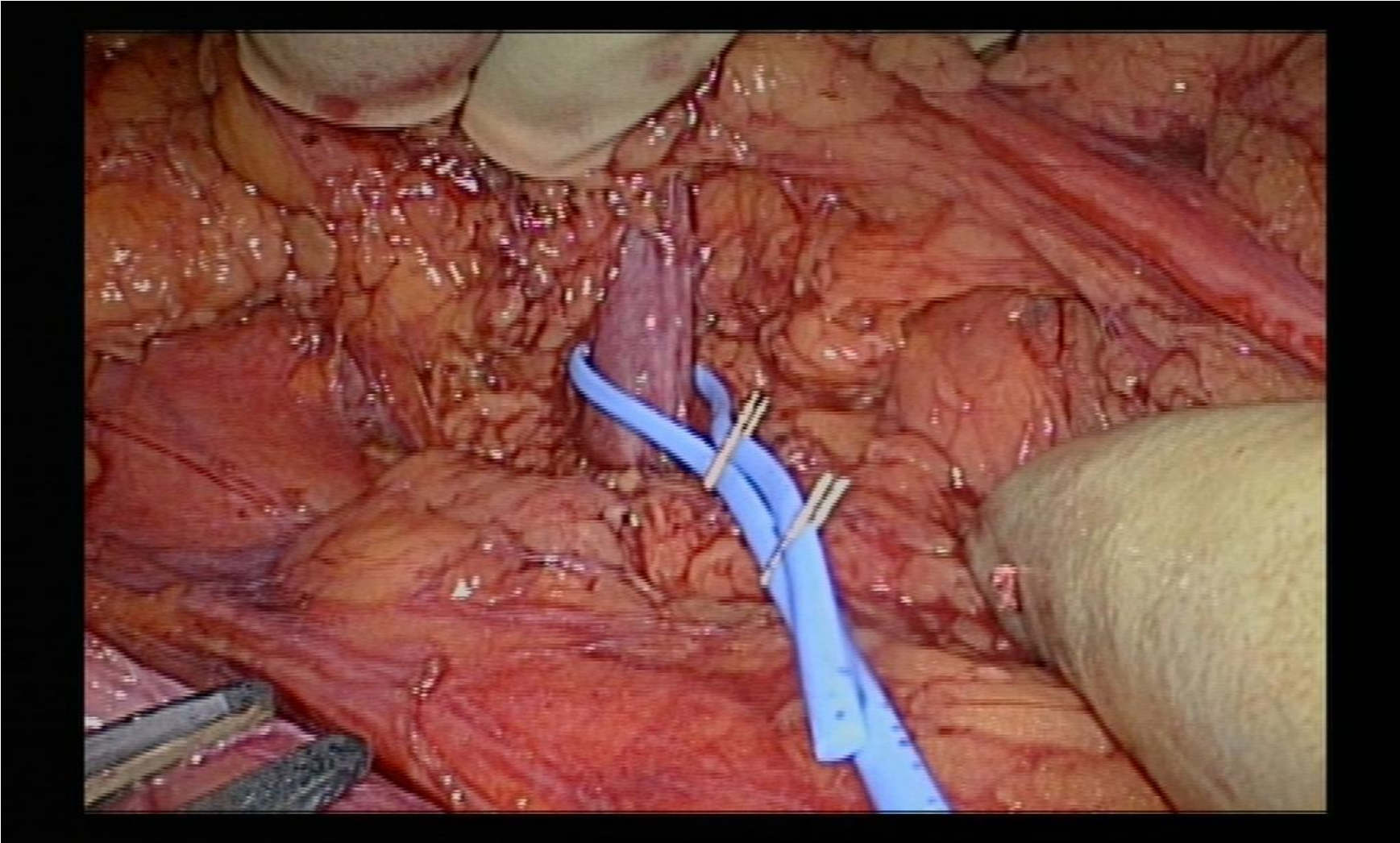
Dissection ureter



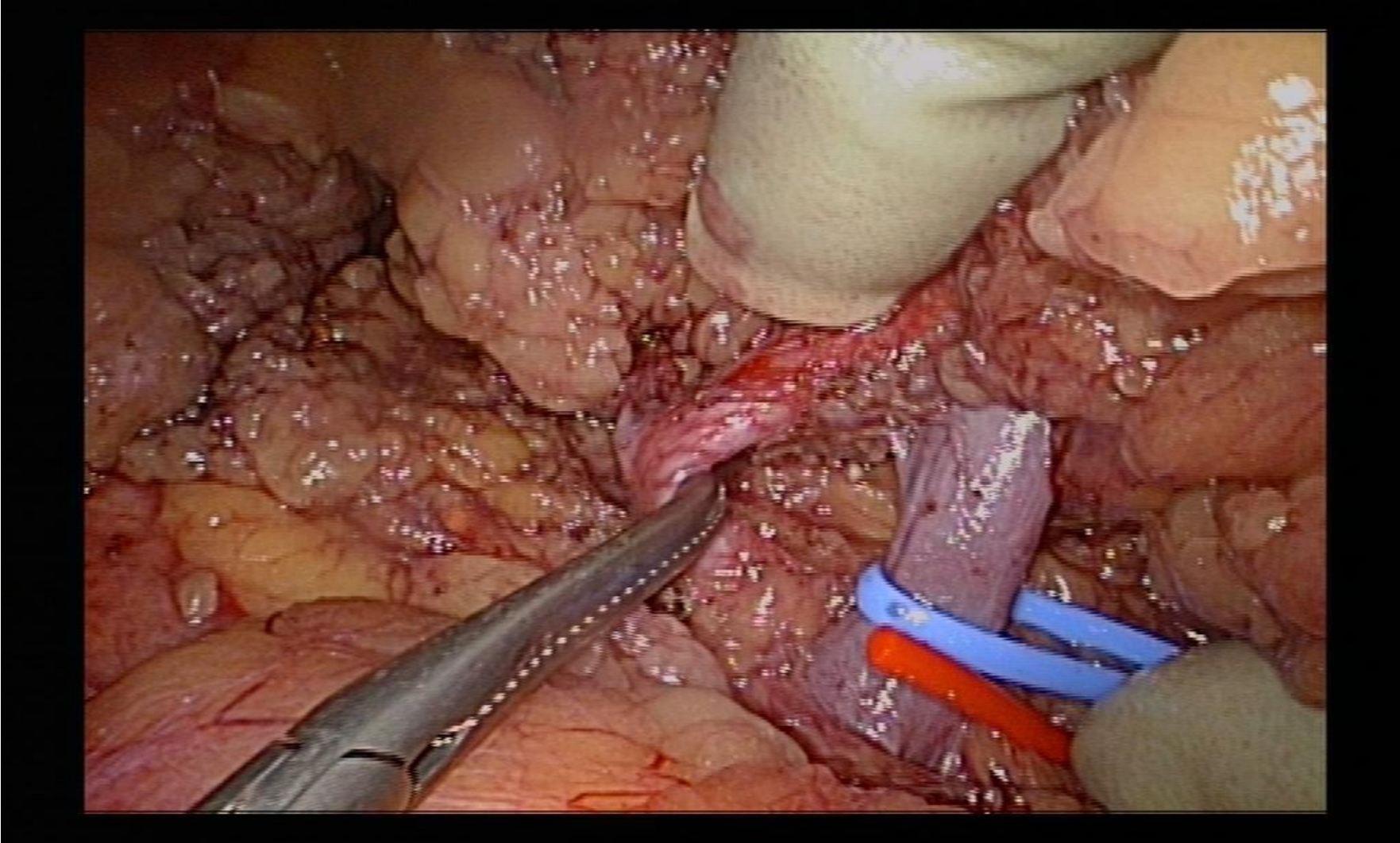
Renal vein



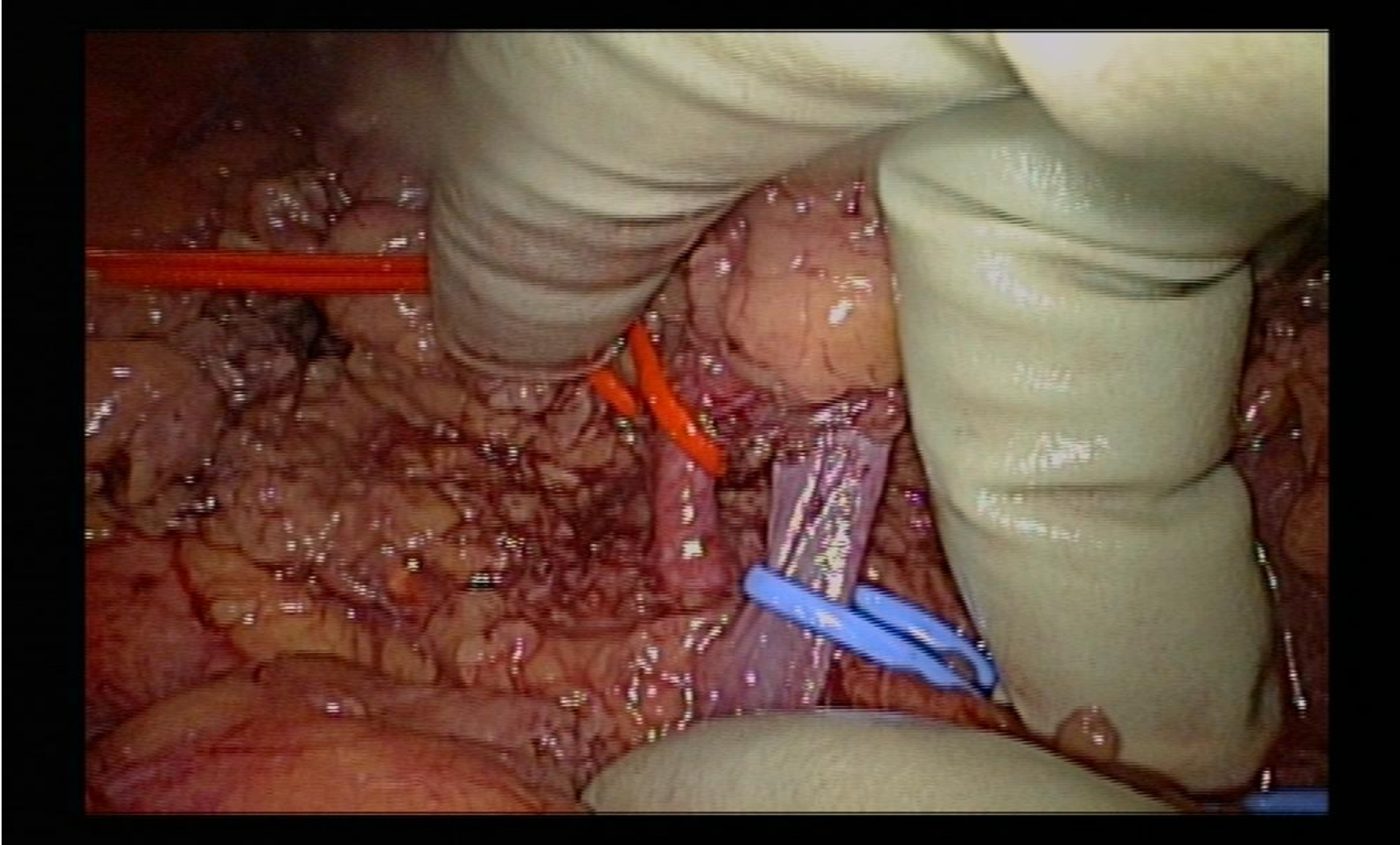
Renal vein



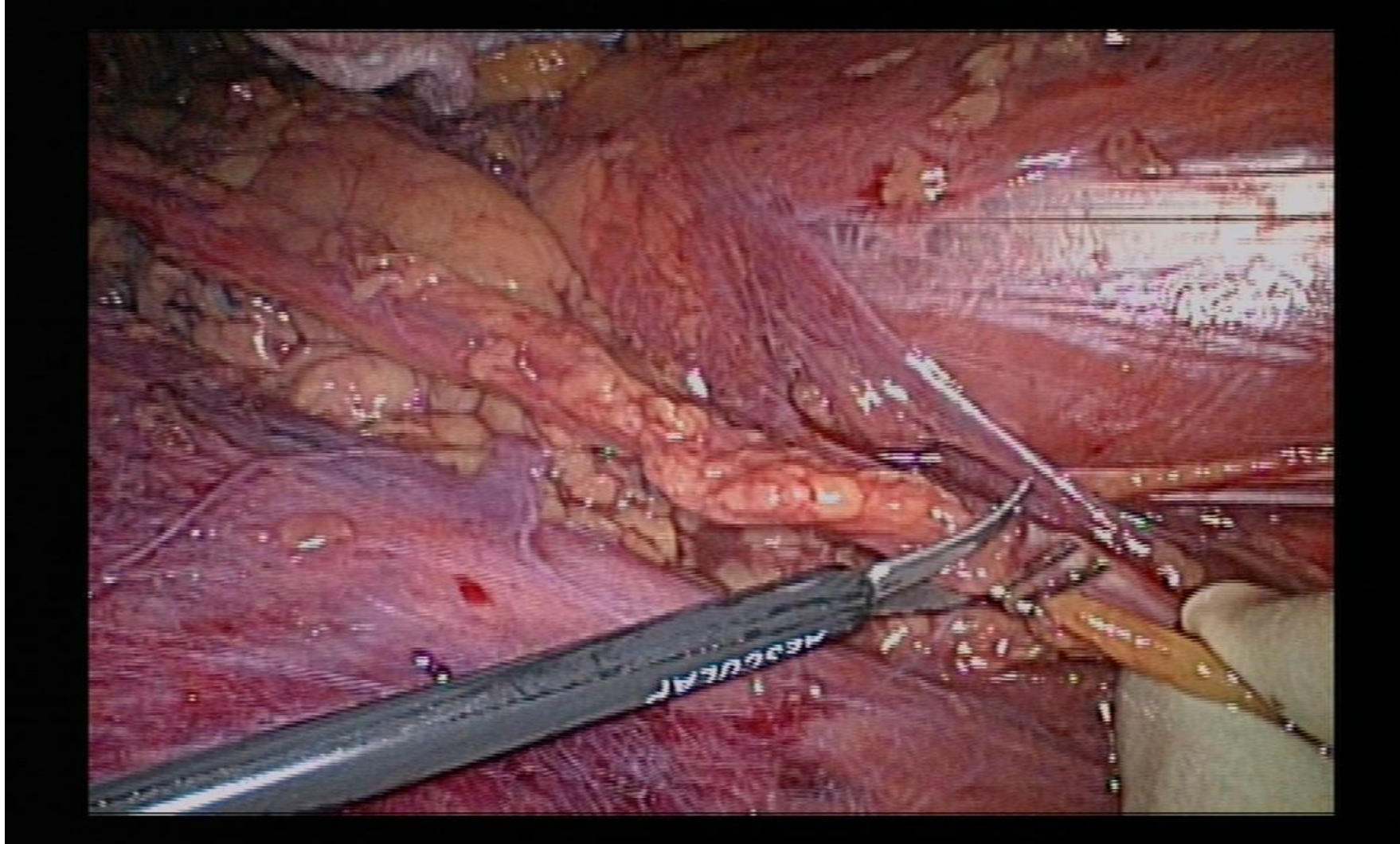
Renal artery



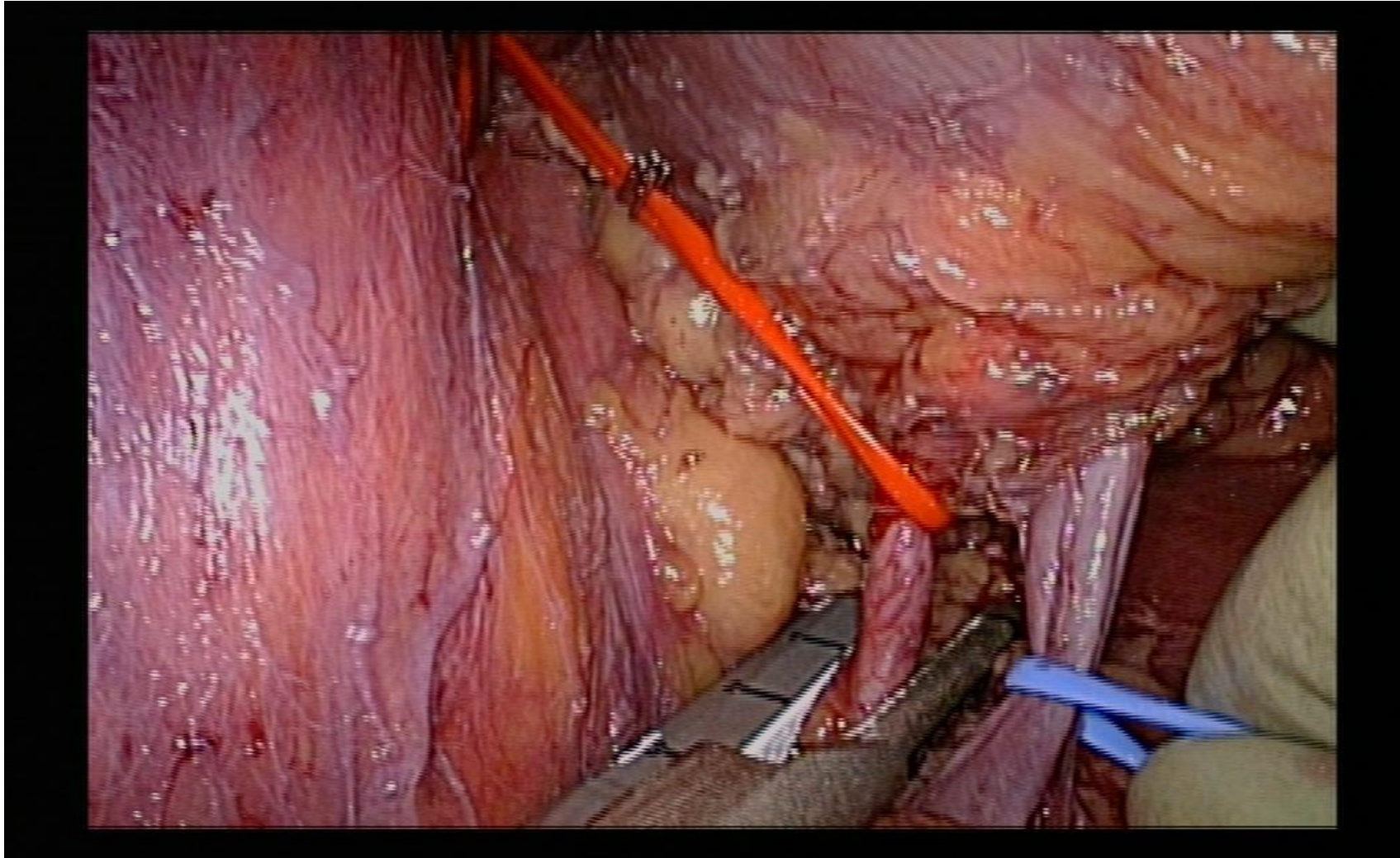
Renal artery



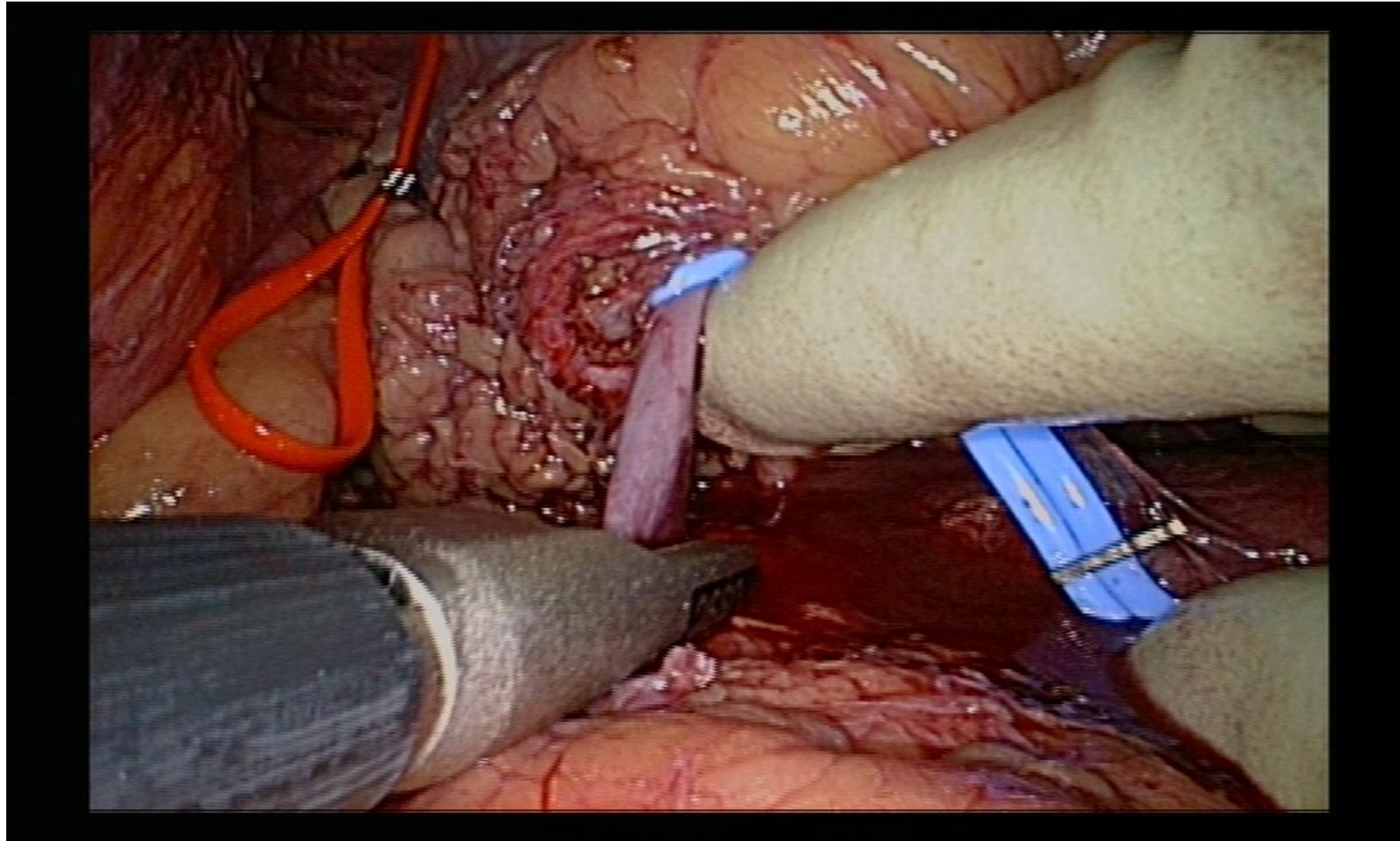
Clipping of the ureter



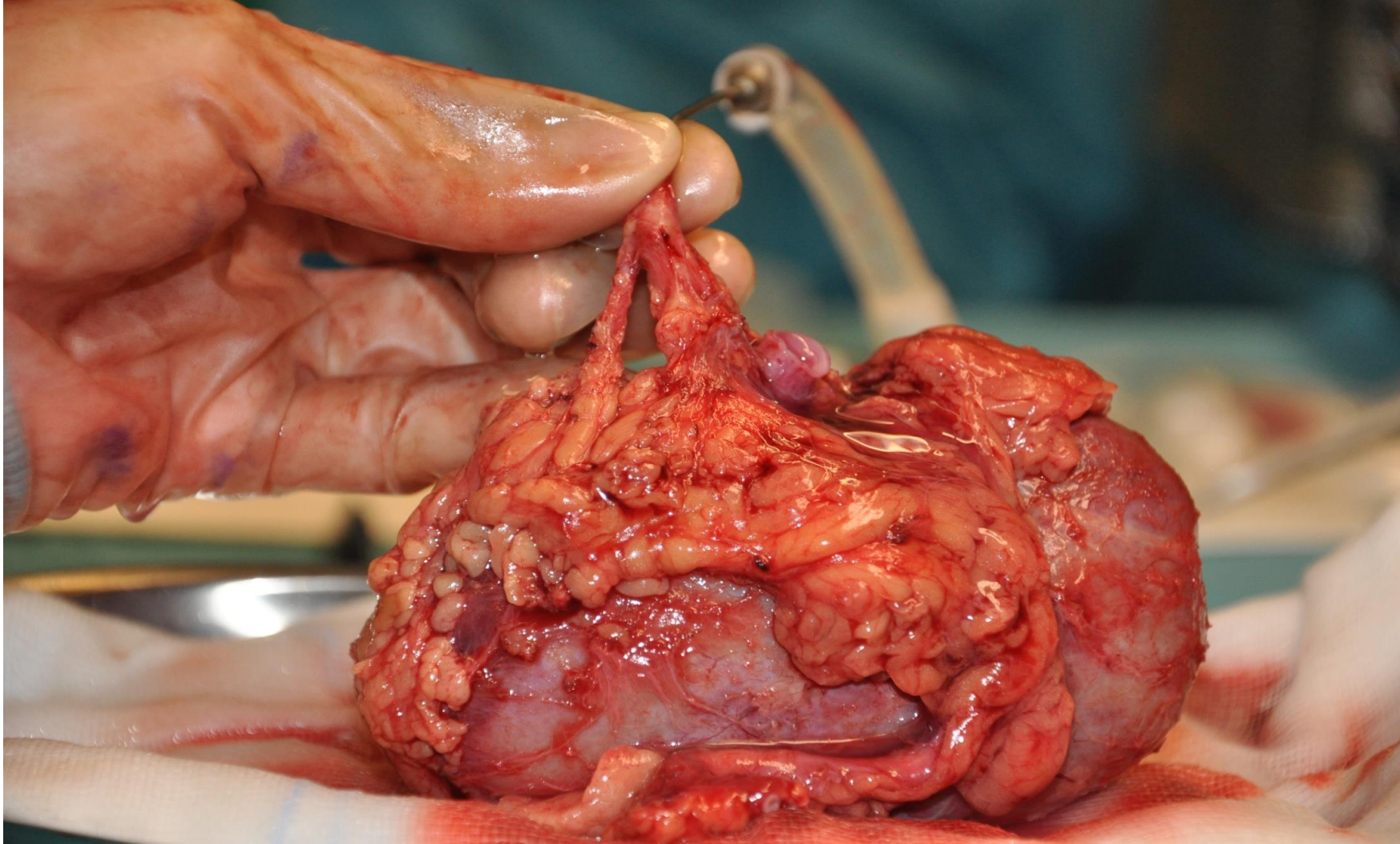
Transsection renal artery



Transsection renal vein



Perfusion of the kidney





LIDO

MASTERCLASS

Thank you